


Original Article

Atorvastatin attenuates D-galactose-induced hepatorenal toxicity in mice: an experimental study with histopathological evaluations

Zahra Taghipour¹, Elham Kaviani², Ayat Kaeidi^{3,4}, Ali Shamsizadeh^{3,4}, Jalal hassanshahi^{3,4}, Iman Fatemi^{3,4*} 

1. Department of Anatomy, Rafsanjan University of Medical Sciences, Rafsanjan, Iran

2. Student Research Committee, Rafsanjan University of Medical Sciences, Rafsanjan, Iran

3. Physiology-Pharmacology Research Center, Research Institute of Basic Medical Sciences, Rafsanjan University of Medical Sciences, Rafsanjan, Iran

4. Department of Physiology and Pharmacology, School of Medicine, Rafsanjan University of Medical Sciences, Rafsanjan, Iran

Abstract

Introduction: Atorvastatin (Ator) is a lipid lowering drug with potent antioxidant and anti-inflammatory properties. The present investigation was designed to study the effect of Ator on D-galactose (GAL)-induced hepatorenal toxicity in mice.

Methods: In this study, 40 mice were divided into 4 groups: normal, GAL (500 mg/kg), Ator 0.1 (0.1mg/kg)+GAL and Ator 1 (1mg/kg)+GAL. Ator and GAL were administered orally for 6 weeks simultaneously. Then on day 43, blood samples were collected to determine blood urea nitrogen (BUN), serum creatinine (sCr), aspartate aminotransferase (AST) and alanine aminotransferase (ALT) levels. The kidneys and livers samples were used for histological examination.

Results: Our results indicated that administration of GAL significantly increases sCr, BUN, ALT and AST. Co-administration of Ator 0.1 and 1mg/kg with GAL for 6 weeks (especially 1mg/kg) attenuated these changes. Histological changes in kidney such as infiltration of leukocyte, necrosis and oedema were observed in GAL group. Moreover, pyknosis, infiltration of inflammatory cell and fat deposit were observed in the livers of GAL-treated mice. Co-administration of Ator 0.1 and 1mg/kg with GAL for 6 weeks (especially 1mg/kg) could mitigate the histological lesions in kidneys and livers of GAL-administered animals.

Conclusion: The results of this study suggested that Ator may have beneficial effects on hepatorenal toxicity induced by GAL.

Keywords:

Hepatorenal toxicity;
D-galactose;
Atorvastatin

Received: 22 Aug 2018

Accepted: 18 Feb 2019

*Correspondence to:

I. Fatemi

Cell: +98-9133431737

Tel: +98-3431315083

Fax: +98-3431315003

Email:

imanfatemi@gmail.com

Introduction

Atorvastatin (Ator) is one of the most commonly consumed drugs which administered for patients with

atherosclerotic and hyperlipidemic (Schachter, 2005). Ator is a 3-hydroxy-methyl-glutaryl coenzyme A reductase inhibitor which decrease the production of cholesterol (Athysos et al., 2004). Ator has other well-established properties such as anti-oxidant, anti-

aging, anti-inflammatory and analgesic effects (Bedi et al., 2016). It has been shown that Ator improves pathological changes in naturally aged kidney via increasing the expression of peroxisome proliferator-activated receptor as well as decreasing the expression of matrix metalloproteinase-9 and transforming growth factor- β 1 in the kidney (Zhao et al., 2016). Furthermore, the nephroprotective properties of Ator has been shown in different pathological conditions such as ischemic acute renal failure and contrast-induced nephropathy (Pisani et al., 2002; He et al., 2017). On the other hand, it has also been reported that Ator has hepatoprotective effects against the lipemic-oxidative disorder and ischemia-reperfusion injury (Amin and El-Twab, 2009; Ajamieh et al., 2015).

D-galactose (GAL) is a natural sugar which is found in the body in normal conditions. At the normal level, GAL is completely converted into glucose (Xu et al., 2009). But at the high level, GAL could produce reactive oxygen species (ROS) in different organs such as liver and kidney (Wei et al., 2005). Recently, it was demonstrated that GAL-induced oxidative damage is associated with inflammatory reactions (Wei et al., 2005). Therefore, mice treated with GAL could serve as a good model for oxidative damage research (Fatemi et al., 2018a).

The object of current investigation was to explore the possible protective effect of Ator on GAL-induced hepatorenal toxicity in mice by histopathological evaluations.

Materials and methods

Animals

Forty male mice (18 to 22g) were purchased from Animal House of Rafsanjan University of Medical Sciences, Iran. The animals were maintained in standard conditions (temperature: $22\pm 2^{\circ}\text{C}$ and 12h light/dark cycle). Food and water were given *ad libitum*. All the animal procedures were carried out in accordance with the standard ethical guidelines (NIH, publication no. 85-23, revised 1985) and approved by the Institutional Animal Care and use Committee of Rafsanjan University of Medical Sciences (Ethical code: IR.RUMS.REC.1397.155).

Drugs

Ator (LipitorTM) was obtained from Pfizer

Pharmaceuticals company (USA). GAL was obtained from Sigma-Aldrich company (Germany). Drugs were dissolved in standard drinking water (in a volume of 10ml/kg body weight of drinking water) and administered orally to treated mice once a day for 6 weeks (Kaviani et al., 2017; Fatemi et al., 2018b).

Experimental design

After 2 weeks of acclimatization, mice were divided into 4 groups (n=10). Group I (normal): healthy normal animals without any intervention; group II (GAL): mice treated with GAL 500mg/kg; group III (GAL+Ator 0.1): mice treated with GAL plus Ator 0.1 mg/kg/day and group IV (GAL+Ator 1): mice treated with GAL plus Ator 1 mg/kg/day

Sample collection

On the 43th day, the experimental animals were given deep diethyl ether anesthesia. Then, blood samples were taken via the cardiac puncture method. Serum was separated by centrifugation for 10min at 3000rpm and stored at -20°C . Then, animals were sacrificed by decapitation and the kidney and liver tissues were carefully removed and washed with ice-cold saline. The kidneys and liver samples were fixed in 10% formalin.

Biochemical analysis

Blood urine nitrogen (BUN), serum creatinine (sCr), alanine aminotransferase (ALT) and aspartate aminotransferase (AST) levels were assessed by the MINDRAY autoanalyzer (China) with specific test kits (Technicon, Bayer S.A. Diagnostic).

Histopathological evaluations

The fixed liver and kidney samples were processed in an Auto-Technicon machine. Then, the paraffin blocks were prepared and cut into $5\mu\text{m}$ sections. The sections were stained with hematoxylin and eosin (H&E). The following indices were assessed in the kidney: leukocyte infiltration as well as oedema and necrosis. Also, the following indices were assessed in the liver: congestion of RBC, infiltration of inflammatory cell, pyknosis and fat deposit. We scored these histopathological indices according to previous studies: 0= normal, 1= mild, 2= moderate and 3= severe (Ehsani et al., 2017; Ghaznavi et al., 2017; Mehrzadi et al., 2018).

Statistical analysis

The results were presented as mean±SEM. The differences between groups were analyzed with one-way analysis of variance (ANOVA) followed by Tukey's post hoc test. Non-parametric variable (pathological indices) were analyzed by Kruskal-Wallis followed by Dunn's post hoc test. Differences in data were considered as significant if $P<0.05$.

Results

The effect of Ator on the kidney function tests

sCr and BUN are two valid markers for evaluating the kidney function. As shown in Figure 1A, the levels of

sCr were increased in the GAL-administered mice in comparison with the normal animals ($P<0.001$). Moreover, administration of Ator at the doses 0.1 and 1mg/kg attenuated GAL-induced enhancement of sCr level ($P<0.05$ and $P<0.001$, respectively). As shown in Figure 1B, BUN levels were elevated in the GAL-treated animals in comparison with the normal group ($P<0.001$). Furthermore, Ator treatment at the doses 0.1 and 1mg/kg reduced the BUN level in GAL-treated mice ($P<0.05$ and $P<0.01$, respectively)

The effect of Ator on the liver function tests

AST and ALT are biochemical parameters of liver function. As shown in Figure 2, levels of AST and

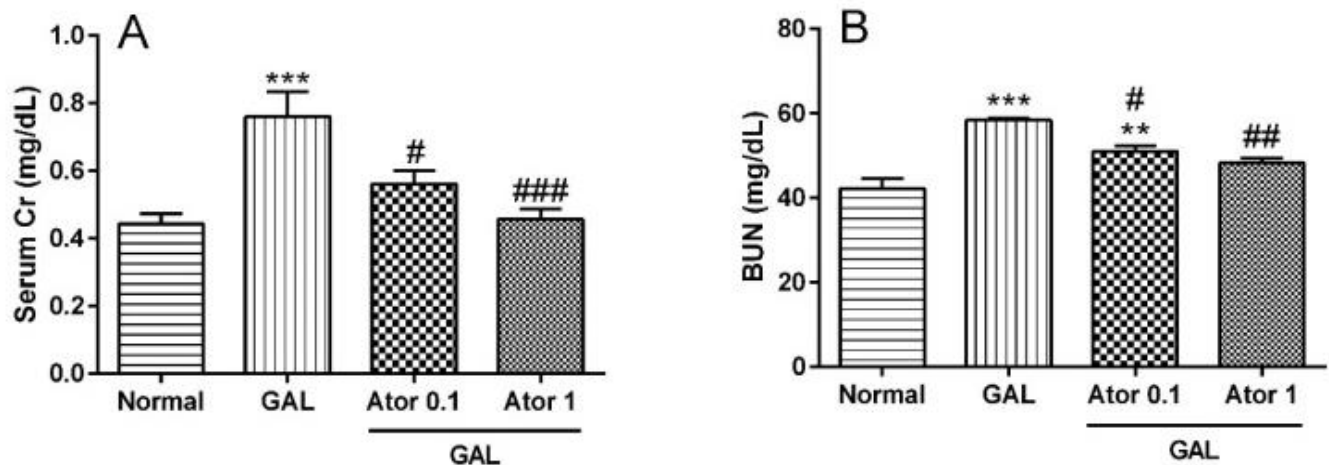


Fig.1. Effect of treatment with Ator on serum Cr and BUN levels in GAL-induced hepatorenal toxicity. Values are means±SEM (n=10). Data were analyzed by one-way ANOVA followed by Tukey's post hoc test for multiple comparisons. *significant difference in comparison with the normal group (** $P<0.01$ and *** $P<0.001$). #significant difference in comparison with the GAL group (# $P<0.05$, ## $P<0.01$ and ### $P<0.001$).

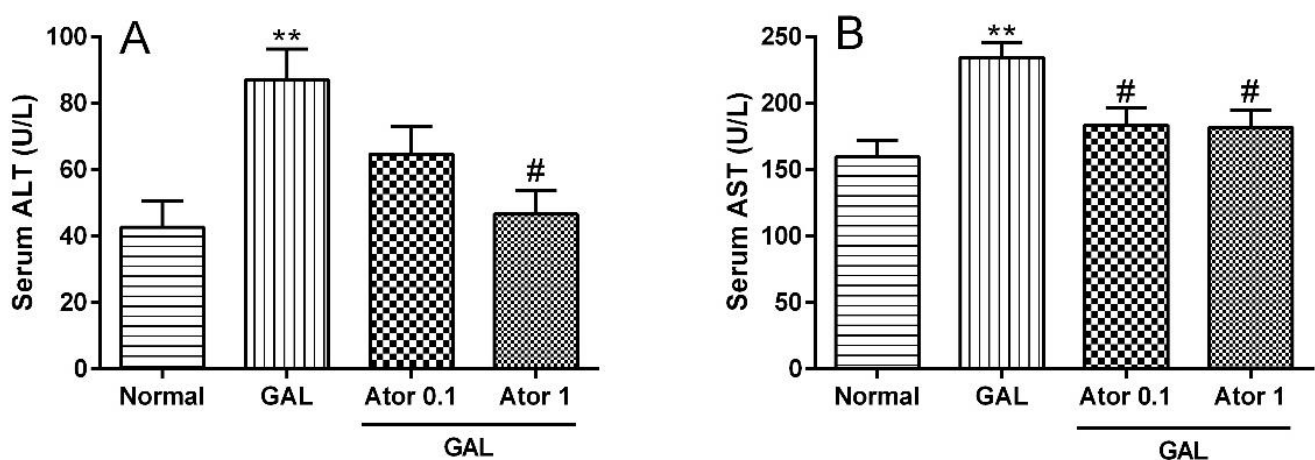


Fig.2. Effect of treatment with Ator on serum ALT and AST levels in GAL-induced hepatorenal toxicity. Values are means±SEM (n=10). Data were analyzed by one-way ANOVA followed by Tukey's post hoc test for multiple comparisons. *significant difference in comparison with the normal group (** $P<0.01$). #significant difference in comparison with the GAL group (# $P<0.05$).

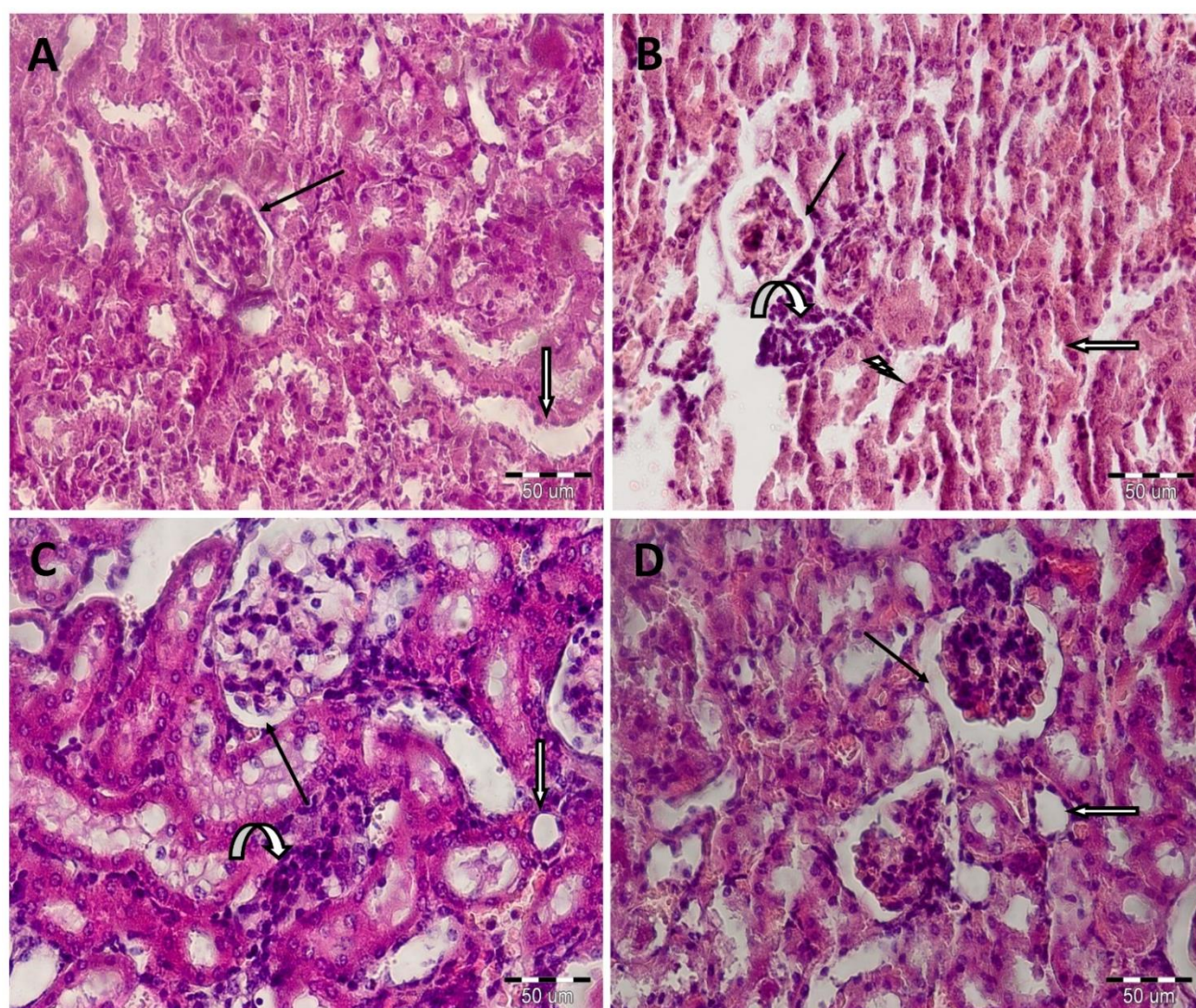


Fig.3. Histopathological observations (kidney sections stained with Hematoxylin & Eosin, magnification X 40) showing effects of Ator on GAL-induced nephrotoxicity changes in kidney. (A) normal group; (B) GAL group; (C) Ator 0.1+GAL group and (D) Ator 1+GAL group. Line arrow: the urine space of the Bowman capsule; White arrow: lumen of the collecting tubes; Bent arrow: infiltration of inflammatory cells; Lightning bolt: tubular necrosis.

Table 1: The histopathological changes of mice kidneys in Hematoxylin & Eosin stained sections

| Histological criteria | Groups | | | |
|---|--------|--------------------------|----------------------|-------------------------|
| | Normal | GAL | GAL+Ator 0.1 | GAL+Ator 1 |
| Leukocyte infiltration | 0.0 | 3.16±0.3 ^{***} | 2.5±0.22 | 0.5±0.22 ^{###} |
| Oedema | 0.0 | 3.28±0.28 ^{***} | 1±0.3 ^{###} | 0.4±0.2 ^{###} |
| Necrosis | 0.0 | 2.14±0.14 ^{***} | 1.85±0.26 | 0.0 ^{###} |
| Values are means±SEM (n=10). [*] significant with normal group (^{***} <i>P</i> <0.001). [#] significant with GAL group (^{###} <i>P</i> <0.001). | | | | |

ALT were increased in the GAL group in comparison with the normal group (all *P*<0.01). Administration of Ator (0.1mg/kg) decreased the AST level in GAL-treated animals (*P*<0.05). Moreover, administration of Ator at the dose 1mg/kg attenuated the ALT and AST

elevations induced by GAL (*P*<0.05).

The effect of Ator on the histopathological changes

We used H&E staining to assess the effect of Ator on

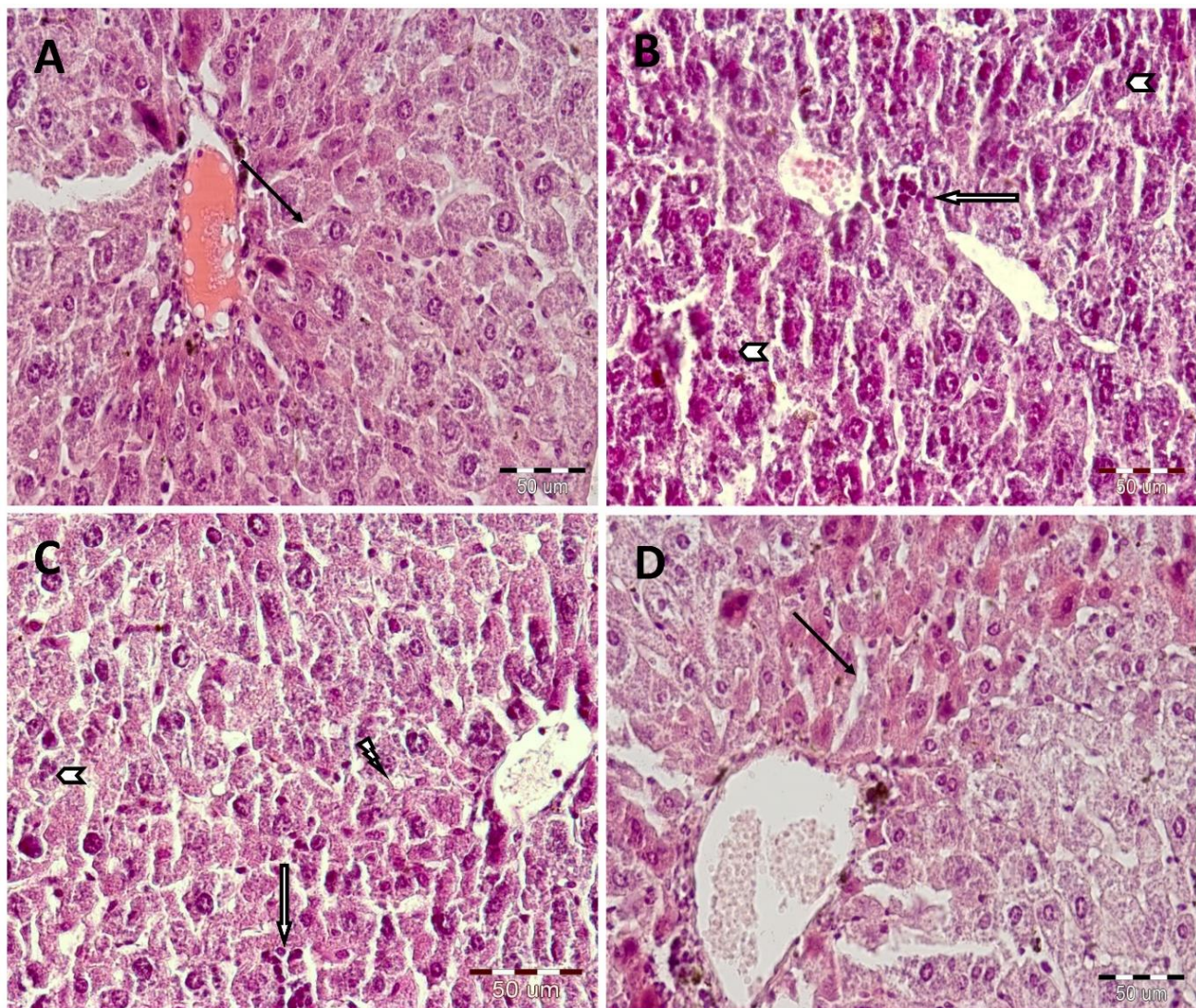


Fig.4. Histopathological observations (liver sections stained with Hematoxylin & Eosin, magnification X 40) showing effects of Ator on GAL-induced hepatotoxicity changes in liver. (A) normal group; (B) GAL group; (C) Ator 0.1+GAL group and (D) Ator 1+GAL group. Line arrow: sinusoids; Chevron: pyknosis; Lightning bolt: fat deposit; white arrow: infiltration of inflammatory cells.

Table 2: The histopathological changes of mice livers in Hematoxylin & Eosin stained sections

| Histological criteria | Groups | | | |
|------------------------------------|--------|-------------------------|-----------------------|-------------------------|
| | Normal | GAL | GAL+Ator 0.1 | GAL+Ator 1 |
| Infiltration of inflammatory cells | 0.0 | 2.4±0.24 ^{***} | 2.2±0.2 | 0.2±0.2 ^{###} |
| Fat deposit | 0.0 | 3.4±0.24 ^{***} | 2.4±0.24 [#] | 0.8±0.2 ^{###} |
| Pyknosis | 0.0 | 3.3±0.21 ^{***} | 2±0.25 ^{###} | 0.5±0.22 ^{###} |

Values are means±SEM (n=10). * significant with normal group (^{***} $P<0.001$). # significant with GAL group ([#] $P<0.05$ and ^{###} $P<0.001$).

hepatorenal injuries induced by GAL. Histology survey of the kidney sections in normal group displayed the normal glomeruli and the urine space of the Bowman capsule, the lumens of the collecting tubes were obvious and there is no evidence of

necrosis and inflammation (Fig 3A and Table 1). Massive damages were found in kidney tissues of GAL-administered mice (infiltration of leukocyte, necrosis and oedema) (all $P<0.001$, Fig. 3B and Table 1). Administration of Ator at the doses

0.1mg/kg reduced the oedema compared to the GAL-administered animals ($P<0.001$). In this group, the collecting tubes are more obvious than GAL group. Also, there was no evidence of necrosis but inflammation was seen (Fig. 3C and Table 1). Moreover, administration of Ator (1mg/kg) effectively improved the kidney morphology and ameliorated pathological score of kidneys compared to the GAL-administered animals (all $P<0.001$). In Ator 1 group, the glomeruli, the urine space of the Bowman capsule and the lumen of collecting tubes were obvious. Also, there was no evidence of edema, necrosis and inflammation (Fig. 3D and Table 1).

The normal animals displayed a normal liver morphology (Fig. 4A and Table 2). In the GAL-administered animals, extensive damages were observed in liver tissues such as leukocyte infiltration, pyknosis and fat deposit. Also, sinusoids were not clear in these animals (all $P<0.001$, Fig. 4B and Table 2). Administration of Ator (0.1mg/kg) to GAL-treated mice reduced the severity of histopathological indices such as pyknosis and fat deposit of liver ($P<0.001$ and $P<0.05$, respectively; Fig. 4C and Table 2). The improving effect of Ator (1mg/kg) on GAL-treated mice was clearly obvious. We also found that the histopathological indices of these animals did not show a significant difference compared with the normal mice (all $P<0.001$). In Ator 1 group, central vein and sinusoids were obvious (Fig. 4D and Table 2).

Discussion

In the current study, we investigated the protective effect of Ator on hepatorenal toxicity induced by GAL in mice. The results indicated that administration of GAL (500mg/kg for 6 weeks) results in significant renal and hepatic toxicity as evidenced by the increase in biochemical markers such as sCr, BUN, ALT and AST levels. Also, it was found that these biochemical alternations are in parallel with the kidney and liver histopathological results. GAL administration increased the histopathological indices in the liver and kidney. Furthermore, Ator treatment at the dose of 0.1 and 1mg/kg for 6 weeks (especially 1mg/kg) could improve GAL-induced renal and hepatic toxicity by regulating the levels of sCr, BUN, ALT and AST. Also, Ator treatment significantly ameliorated the histopathological alternations of the

liver and kidney tissues induced by GAL.

It has been demonstrated that chronic administration of GAL promotes oxidative stress in different organs such as liver and kidney. Oxidative stress induces the histopathological changes in liver and kidney which are characterized by increasing the levels of sCr, BUN, ALT and AST. Our results demonstrated that oral administration of GAL elevates the above-mentioned parameters. We also found that Ator treatment (especially 1mg/kg) decreases the above-mentioned parameters compared to the GAL-administered animals. Previous reports have demonstrated that antioxidant agents such as luteolin, troxerutin, carnosine and taurine attenuated these alternations in GAL-induced hepatorenal injuries (Fan et al., 2009; Kalaz et al., 2014; Xu et al., 2015). On the other hand, the antioxidant effects of statins such as Ator has been demonstrated in several studies. It was demonstrated that statins decrease the ROS production in endothelial cells through increasing the thioredoxin activity (Haendeler et al., 2004). Simvastatin reduced the over-production of free radicals in stimulated macrophages (Girona et al., 1999). It was shown that Ator reduces the levels of malondialdehyde as well as increases the activity of superoxide dismutase (SOD) in a rat model of Parkinson's disease (Prajapati et al., 2017). In another study, Mehrzadi et al. (2016) demonstrated that Ator increased the activity of SOD and suppresses renal oxidative stresses in gentamicin-induced nephrotoxicity in rat. Therefore, it is possible that Ator exerts these protective effects via antioxidant effects and increasing the antioxidative capacity.

Available data have suggested that over-production of ROS could cause tissue inflammation which is associate with tissue damage and cell death (Majsterek et al., 2005). In accordance with biochemical evaluations, histopathological results demonstrating structural changes in liver and kidney tissue of GAL-administered mice. In kidney, lesions like infiltration of leukocyte, necrosis and oedema were found. Lesions like fat deposit, leukocyte infiltration and pyknosis were found in liver. Histopathological results of current study are in line with the previous reports (Fan et al., 2009; Kalaz et al., 2014; Xu et al., 2015). We also demonstrated that administration of Ator at the dose of 0.1 and 1mg/kg for 6 weeks (especially 1mg/kg) causes considerable

improvement in pathological changes of liver and kidney. On the other hand, the hepatorenal protective effects of Ator has been confirmed in different oxidative conditions by histopathological evaluations. It was reported that Ator has a renoprotective effects against contrast and diabetes-induced kidney injuries and significantly attenuated kidney histopathological changes (Zhou et al., 2014; Yue et al., 2017). Moreover, Ator effectively improves liver histopathological alterations in hepatotoxicity induced by ischemia-reperfusion and doxorubicin (Ajamieh et al., 2012; El-Moselhy and El-Sheikh, 2014).

The limitation of current study was some financial restriction that limited us from evaluating the oxidative stress and inflammation parameters in order to unveil the underlying mechanism of the Ator in GAL-induced renal and hepatic toxicity.

Conclusion

This study investigated the effects of Ator on hepatorenal pathology in GAL-treated mice. For the first time we showed that administration of Ator to GAL-administered mice decreased the hepatorenal damages as well as attenuated the histopathological lesions of liver and kidney. However, more evidence is needed to explain the precise mechanism underlying the benefits of Ator. Hence, Ator might be a new therapeutic approach in mitigating hepatorenal oxidative damages in humans.

Acknowledgments

This study was funded by Deputy of Research of Rafsanjan University of Medical Sciences, Rafsanjan, Iran (Grant number: 97264).

Conflict of interest

Authors declare no conflict of interest related to this work.

References

- Ajamieh H, Farrell G, Wong HJ, Yu J, Chu E, Chen J, et al. Atorvastatin protects obese mice against hepatic ischemia-reperfusion injury by Toll-like receptor-4 suppression and endothelial nitric oxide synthase activation. *J Gastroenterol Hepatol* 2012; 27: 1353-61.
- Ajamieh H, Farrell GC, McCuskey RS, Yu J, Chu E, Wong HJ, et al. Acute atorvastatin is hepatoprotective against ischaemia-reperfusion injury in mice by modulating eNOS and microparticle formation. *Liver Int* 2015; 35: 2174-86.
- Amin KA, Abd El-Twab TM. Oxidative markers, nitric oxide and homocysteine alteration in hypercholesterolemic rats: role of atorvastatin and cinnamon. *Int J Clin Exp Med* 2009; 2: 254-65.
- Athyros VG, Mikhailidis DP, Papageorgiou AA, Symeonidis AN, Pehlivanidis AN, Bouloukos VI, et al. The effect of statins versus untreated dyslipidaemia on renal function in patients with coronary heart disease. A subgroup analysis of the Greek atorvastatin and coronary heart disease evaluation (GREACE) study. *J Clin Pathol* 2004; 57: 728-34.
- Bedi O, Dhawan V, Sharma PL, Kumar P. Pleiotropic effects of statins: new therapeutic targets in drug design. *Naunyn Schmiedeberg Arch Pharmacol* 2016; 389: 695-712.
- Ehsani V, Amirteimoury M, Taghipour Z, Shamsizadeh A, Bazmandegan G, Rahnama A, et al. Protective effect of hydroalcoholic extract of *Pistacia vera* against gentamicin-induced nephrotoxicity in rats. *Ren Fail* 2017; 39: 519-525.
- El-Moselhy MA, El-Sheikh AA. Protective mechanisms of atorvastatin against doxorubicin-induced hepato-renal toxicity. *Biomed Pharmacother* 2014; 68: 101-10.
- Fan SH, Zhang ZF, Zheng YL, Lu J, Wu DM, Shan Q, et al. Troxerutin protects the mouse kidney from d-galactose-caused injury through anti-inflammation and anti-oxidation. *Int Immunopharmacol* 2009; 9: 91-6.
- Fatemi I, Heydari S, Kaeidi A, Shamsizadeh A, Hakimzadeh E, Khaluoi A, et al. Metformin ameliorates the age-related changes of d-galactose administration in ovariectomized mice. *Fundam Clin Pharmacol* 2018a; 32: 392-399.
- Fatemi I, Khaluoi A, Kaeidi A, Shamsizadeh A, Heydari S, Allahtavakoli MA. Protective effect of metformin on D-galactose-induced aging model in mice. *Iran J Basic Med Sci* 2018b; 21: 19-25.
- Ghaznavi H, Fatemi I, Kalantari H, Hosseini Tabatabaei SMT, Mehrabani M, Gholamine B, et al. Ameliorative effects of gallic acid on gentamicin-induced nephrotoxicity in rats. *J Asian Nat Prod Res* 2017; 1-12.
- Girona J, La Ville AE, Sola R, Plana N, Masana L. Simvastatin decreases aldehyde production derived from lipoprotein oxidation. *Am J Cardiol* 1999; 83: 846-51.
- Haendeler J, Hoffmann J, Zeiher AM, Dimmeler S. Antioxidant effects of statins via S-nitrosylation and activation of thioredoxin in endothelial cells: a novel vasculoprotective function of statins. *Circulation* 2004; 110: 856-61.
- He X, Yang J, Li L, Tan H, Wu Y, Ran P, et al. Atorvastatin protects against contrast-induced nephropathy via anti-apoptosis by the upregulation of Hsp27 in vivo and in vitro. *Mol Med Rep* 2017; 15: 1963-1972.
- Kalaz EB, Coban J, Aydin AF, Doğan-Ekici I, Doğru-Abbasoglu S, Oztezcan S, et al. Carnosine and taurine treatments decreased oxidative stress and tissue

- damage induced by D-galactose in rat liver. *J Physiol Biochem* 2014; 70: 15-25.
- Kaviani E, Rahmani M, Kaeidi A, Shamsizadeh A, Allahtavakoli M, Mozafari N, et al. Protective effect of atorvastatin on d-galactose-induced aging model in mice. *Behav Brain Res* 2017; 334: 55-60.
- Majsterek I, Gloc E, Blasiak J, Reiter RJ. A comparison of the action of amifostine and melatonin on DNA-damaging effects and apoptosis induced by idarubicin in normal and cancer cells. *J Pineal Res* 2005; 38: 254-63.
- Mehrzadi S, Fatemi I, Malayeri AR, Khodadadi A, Mohammadi F, Mansouri E, et al. Ellagic acid mitigates sodium arsenite-induced renal and hepatic toxicity in male Wistar rats. *Pharmacol Rep* 2018; 70: 712-719.
- Mehrzadi S, Kamrava SK, Dormanesh B, Motevalian M, Hosseinzadeh A, Hosseini Tabatabaei SM, et al. Melatonin synergistically enhances protective effect of atorvastatin against gentamicin-induced nephrotoxicity in rat kidney. *Can J Physiol Pharmacol* 2016; 94: 265-71.
- Pisani A, Uccello F, Cesaro A, Comi N, Mirengi F, Serio V, et al. Effects of atorvastatin on ischemic acute renal failure in aging rats. *G Ital Nefrol* 2002; 19: 534-9.
- Prajapati SK, Garabadu D, Krishnamurthy S. Coenzyme Q10 prevents mitochondrial dysfunction and facilitates pharmacological activity of atorvastatin in 6-OHDA induced dopaminergic toxicity in rats. *Neurotox Res* 2017; 31: 478-492.
- Schachter M. Chemical, pharmacokinetic and pharmacodynamic properties of statins: an update. *Fundam Clin Pharmacol* 2005; 19: 117-25.
- Wei H, Li L, Song Q, Ai H, Chu J, Li W. Behavioural study of the D-galactose induced aging model in C57BL/6J mice. *Behav Brain Res* 2005; 157: 245-51.
- Xu Y, Wu T, Jin Y, Fu Z. Effects of age and jet lag on D-galactose induced aging process. *Biogerontology* 2009; 10: 153-61.
- Xu Y, Zhang J, Liu J, Li S, Li C, Wang W, et al. Luteolin attenuate the D-galactose-induced renal damage by attenuation of oxidative stress and inflammation. *Nat Prod Res* 2015; 29: 1078-82.
- Yue R, Zuo C, Zeng J, Su B, Tao Y, Huang S, et al. Atorvastatin attenuates experimental contrast-induced acute kidney injury: a role for TLR4/MyD88 signaling pathway. *Ren Fail* 2017; 39: 643-651.
- Zhao J, Cheng Q, Ye P, Yang G, Liu S, Ao Q, et al. Atorvastatin improves pathological changes in the aged kidney by upregulating peroxisome proliferator-activated receptor expression and reducing matrix metalloproteinase-9 and transforming growth factor- β 1 levels. *Exp Gerontol* 2016; 74: 37-42.
- Zhou S, Zhao P, Li Y, Deng T, Tian L, Li H. Renoprotective effect of atorvastatin on STZ-diabetic rats through attenuating kidney-associated dysmetabolism. *Eur J Pharmacol* 2014; 740: 9-14.